



ELSEVIER



<https://doi.org/10.1016/j.ultrasmedbio.2020.01.032>

● Original Contribution

ULTRASOUND-GUIDED FOCUSED ULTRASOUND TREATMENT FOR PAINFUL BONE METASTASES: A PILOT STUDY

LEAH DROST, KULLERVO HYNYNEN, YUEXI HUANG, BENJAMIN LUCHT, ERIN WONG, GREGORY CZARNOTA, CAITLIN YEE, BO ANGELA WAN, VITHUSHA GANESH, EDWARD CHOW, and ELIZABETH DAVID
Sunnybrook Health Sciences Centre, University of Toronto, Toronto, Ontario, Canada

(Received 19 April 2019; revised 20 January 2020; in final form 29 January 2020)

Abstract—Focused ultrasound (FUS) for palliation of bone metastases has typically been performed under magnetic resonance guidance. To address limitations of this approach, this pilot study evaluated a stand-alone, portable FUS device guided by diagnostic ultrasound alone (ultrasound [US]-guided FUS). Nine patients were treated; safety and efficacy were assessed for 10 d after the procedure, and medical charts were evaluated to assess durability of pain response. The procedure was safe and tolerable, with four patients reporting minor skin-related irritations. Average pain score decreased from 6.9 at baseline to 3.2 at day 10; analgesic use on average also decreased from baseline to day 10. Six patients had durable pain relief as assessed after the follow-up period. Our study provides evidence that US-guided FUS is a safe, tolerable and versatile procedure. It appears to be effective in achieving durable pain response in patients with painful bone metastases. Further research is required to refine the technology and optimize its efficacy. (E-mail: Edward.Chow@sunnybrook.ca) © 2020 World Federation for Ultrasound in Medicine & Biology. All rights reserved.

Key Words: Bone metastases, High-intensity focused ultrasound, Tolerability.

INTRODUCTION

Bone metastases are common in patients with advanced cancer and are often a significant cause of morbidity. Several studies have found bone metastases to negatively affect quality of life (QOL) (Poulsen et al. 1989; Hird et al. 2009; Lutz et al. 2011; McDonald et al. 2014), making them an important target for palliative therapy. Several treatment modalities currently exist for the palliation of metastatic bone pain. External beam radiotherapy (EBRT) is well documented as an effective palliative treatment option (Poulsen et al. 1989; Hartsell et al. 2005; Lutz et al. 2011; McDonald et al. 2014). However, not all patients respond to this common therapy; approximately 30% are left without pain control after EBRT, and the same proportion of initial responders eventually experience pain recurrence. Additionally, there is a dose limitation to EBRT (Chan et al. 2017). Analgesics, specifically narcotics, are also commonly used to treat pain related to bone metastases (von Moos et al. 2016);

however, these come with side effects that limit their desirability, especially in prolonged use. To address the limitations of these treatment options, scientists have studied the utility of high-intensity focused ultrasound (FUS) for the palliation of bone metastases. An international consensus on the use of FUS for bone metastases indicated that FUS can be considered a primary or secondary palliative treatment option in these patients (Huisman et al. 2015).

As a novel, entirely non-invasive technique, FUS utilizes a beam of high-frequency sound waves concentrated into a small volume to generate frictional heat at a cellular level, resulting in thermal ablation of the tissue (Valero et al. 2010). The high acoustic absorption of cortical bone allows the use of low energy levels to achieve temperatures $>60^{\circ}\text{C}$ at the target location. Two postulated mechanisms for the analgesic effect of FUS on bone include thermal ablation of periosteal nerve endings and ablation of tumor mass (Valero et al. 2010).

Previous generations of FUS devices have featured magnetic resonance (MR) image guidance. These devices have been found, in various clinical trials, to be tolerable, effective and non-invasive in the palliation of metastatic bone pain (Catane et al. 2007; Gianfelice et al. 2008;

Address correspondence to: Edward Chow, Department of Radiation Oncology, Odette Cancer Centre, Sunnybrook Health Sciences Centre, 2075 Bayview Avenue, Toronto, ON, Canada M4N 3M5. E-mail: Edward.Chow@sunnybrook.ca

Liberman et al. 2009; Napoli et al. 2013; Hurwitz et al. 2014; Joo et al. 2015; Chan et al. 2017; Namba et al. 2019); there is also evidence that MR-guided FUS (MRgFUS) for bone metastases has a positive impact on QOL (Harding et al. 2018). However, potential drawbacks of such devices include the cost attached to MR equipment, the immobility of the unit, the complex positioning required of the patient and the long treatment duration. Presently, an alternative to address these challenges is the development of ultrasound-guided FUS (USgFUS). The newly engineered device utilizes a small circular ultrasound ablation device attached to an articulated arm. It can be easily manipulated to the target and produces both therapeutic and diagnostic sound waves, which allow treatment and visualization with the same small footprint. Previous studies have evaluated the safety and efficacy of USgFUS in patients with solid tumors (Orgera et al. 2011; Marinova et al. 2016) and have found USgFUS to be feasible, safe and effective in providing pain control and local tumor response.

This USgFUS device has never been tested in this setting of patients with bone metastases. Our primary objective in this pilot study was to evaluate the tolerance and safety of the USgFUS device for painful bone metastases. Second, this study aimed to evaluate pain reduction and QOL.

METHODS

Study design and population

Institutional research ethics board approval was obtained (REB No. 005-2014), and each patient provided informed consent. Patients made up two groups: group 1 included patients who had received no prior EBRT to the site; group 2 included patients who had EBRT to the site previously. If they had not exceeded the maximum tolerated EBRT to the site, all patients were given the option for EBRT at least 2 wk after the procedure. Patients were enrolled from March 2017 to August 2018. Eligibility/ineligibility criteria are described in Appendix A (see Supplementary Data, online only). The selection of a treatment site required radiographic evidence of bone metastases (osteoblastic or osteolytic) correlated to a clinically painful site (pain score ≥ 2 on a scale of 0–10); eligible areas for treatment were located on the extremities, scapulae, iliac bones or ribs. The lesion was required to be accessible to USgFUS treatment based on imaging data.

USgFUS device and procedure

The USgFUS system and software were developed in-house (Sunnybrook Research Institute, Toronto, ON, Canada; images in Appendix B in the Supplementary Data, online only). The therapeutic transducer array consisted of 1024 elements at a frequency of 516 kHz. A diagnostic imaging transducer (diagnostic ultrasound probe

and system: PA7-4/12 and Sonix Touch, respectively; Ultrasonix Medical Corp., Richmond, BC, Canada) at 5 MHz was integrated at the center of the therapeutic array (12 × 21-mm imaging probe in a 24-mm-diameter central hole in the FUS array) for imaging guidance (optical tracker: Polaris Spectra, Northern Digital Inc., Waterloo, ON, Canada). The ultrasound focus was electronically steered to the target, which could be prescribed graphically over the B-mode ultrasound image (estimated range of motion: 30 × 45 cm laterally, 30 cm vertically). Target points 5–10 mm apart sequentially were used to cover the lesion based on B-mode guidance. Data for local harmonic motion (LHM) analysis were acquired during the treatments; however, these data were not used at the time of treatment to assess progress. The FUS array had a 100-mm outer diameter, and a front-mounted water pad with a flexible membrane was in contact with the patient's skin; this membrane was able to conform to the skin to make acoustic contact across an irregular surface. The ultrasound array was connected to a robotic articulated arm (FlexArm, Wapokoneta, OH, USA) with multi-axis rotation capability that could be freely positioned over the patient's body; this allowed the transducer to be placed parallel to the skin for a wide range of anatomic targets. The arm allowed the device to be rotated $\pm 180^\circ$ about one lateral axis and approximately $\pm 45^\circ$ about the other axes to adjust to the orientation of the patient's skin. The Kapton membrane encasing the FUS array with degassed chilled water was coupled to the patient's skin with degassed ultrasound gel. The system's acoustic power was calibrated using an in-house radiation force balance, with the output acoustic power measured for a variety of input voltages.

Stop buttons were available for both patient and operator when pain became intolerable, motion was detected or non-target sonication was suspected. On the procedure day before initiation of the treatment, patients received diagnostic MR imaging or ultrasound to locate the lesion and ensure the safety and feasibility of treatment. Patients were given light intravenous (IV) sedation and local anesthesia at the treatment site (bupivacaine hydrochloride [Marcaine] 2%). Local anesthetic (bupivacaine) was infiltrated into the periosteum using a 25-gauge needle. Patients were placed in a comfortable position, such that the device had maximal apposition to the target.

The USgFUS device was positioned over the treatment area. When bone was visible in the ultrasound image and there was good acoustic coupling between the device and the skin, the device was locked in place to ensure immobility during sonication. A target point was placed slightly above the bone surface (average: 5 mm, *i.e.*, the hyper-intensity signal of bone interface in ultrasound imaging) and sonicated. Sonication power was increased until the patient's maximum tolerable power was found, and multiple points were treated at that

power. Analgesia used, duration of procedure and vital signs were recorded. The procedure was performed on an outpatient basis.

ASSESSMENTS AND DATA COLLECTION

Demographic (age, sex, primary cancer site and Karnofsky Performance Scale) and baseline data were collected. Sizes of treated lesions before the procedure were measured radiologically by the interventional radiologist performing the procedure. After the procedure, safety and efficacy endpoints were evaluated daily for 10 d. Adverse events (AEs) were reported in daily diaries (see Appendix C in Supplementary Data, online only) and assessed by study personnel using the Common Terminology Criteria for Adverse Events (CTCAE) wherein grade 1 = mild symptoms, grade 2 = moderate, grade 3 = severe, grade 4 = life-threatening and grade 5 = death related to AE (National Cancer Institute 2017). Patients were asked about any abnormal reactions or potential anticipated AEs (rash or burning sensation at treatment site). Efficacy endpoints were evaluated as per the updated international consensus defining partial response, complete response and pain progression (see Appendix D in Supplementary Data, online only) using pain score (from 0–10) and analgesics used (daily oral morphine equivalent dose [OMED]) (Chow *et al.* 2002, 2012). QOL endpoints were assessed at baseline and day 10 using the European Organization for Research and Treatment of Cancer Quality of Life Questionnaire (EORTC QLQ) Core-15-Palliative (C15-Pal) and the EORTC QLQ Bone Metastases-22 (BM22) (see Appendixes E and F, respectively, in Supplementary Data, online only); lower scores indicated better QOL.

Medical charts post-procedure were evaluated retrospectively to assess durability of pain response. All available clinical notes after the procedure until January 2019 were assessed to determine severity of pain at the treated site, and to evaluate any further therapy EBRT patients may have received. Average pain scores, opioid medication intake and QOL scores were calculated.

RESULTS

Nine patients consented to participate. Complete data were obtained for each patient. Patient characteristics and treatment sites/lesion sizes are summarized in Tables 1 and 2, respectively. Seven patients had no previous EBRT to the site (group 1). Two received EBRT before USgFUS: 20 Gy in 5 fractions 1 mo prior, and 8 Gy in 1 fraction 2 wk prior (group 2).

Treatment procedure

Vital signs were stable and within acceptable ranges throughout the procedure. During the procedure, OMED and IV versed doses ranged from 0–46 mg/d and from 0.5–5 mg/mL, respectively. No patients asked to terminate

Table 1. Demographic information

Demographic	N
Age (y)	
30–39	1
40–49	1
50–59	0
60–69	4
70–79	3
Average age	56
Sex	
Female	2
Male	7
Primary cancer site	
Prostate	4
Breast	2
Bladder	1
Lung and colon	1
Cholangiocarcinoma	1
Karnofsky Performance Scale score	
60	1
70	2
80	3
90	2
Unknown	1

the procedure. Five patients pressed the stop button if the sonication became too painful, allowing adjustment of target and continuation of the procedure. The procedure lasted 32.4 min on average (range: 24–40 min). The maximum tolerable acoustic power averaged 37 W (range: 4.6–52.2 W). Sonication ranged from 15–35 s per point, and 2–10 points were sonicated in each patient.

The power used for the LHM pushes ranged from 89.2–110.4 W. The LHM pushes used the maximum voltage of the device; the power varied across different devices used in the study. Sonication power was adjustable in steps of 0.6 Vpp. The exact accessible powers varied depending on device calibration, and were approximately 4.0, 5.3, 6.7, 8.3, 10.0, 11.9, 14.0, 16.2, 18.6, 21.2, 23.9, 26.8, 29.8, 33.1, 36.4, 40.0, 43.7, 47.6, 51.7, 55.9 and 60.3 W.

Safety and tolerability

There were no unanticipated adverse device effects in any procedure. During the procedure, only one AE was

Table 2. Focused ultrasound treatment site and lesion size pre-procedure

Pt ID	Size of lesion (cm)	Treatment site
1	5.6 × 5.0	Rib
2	4.5 × 1.9	Ulna
3	2.0 × 1.1	Rib
4	2.8 × 1.6	Scapula
5	4.8 × 1.4	Rib
6	2.0 × 1.0	Rib
7	5.2 × 3.5	Iliac crest
8	2.4 × 1.8	Scapula
9	1.4 × 1.3	Humerus

Table 3. Adverse events at treatment site

Patient ID	Time point	Adverse event	CTCAE grade
1	Days 2, 7, 9, 10	Itch	1
1	Days 3–6, 10	Pain	1
4	Days 1, 2	Redness	1
6	Day 1	Pain	2
8	Days 1, 2	Pain	1

CTCAE = Common Terminology Criteria for Adverse Events

Table 4. Expected adverse events over baseline and follow-up period

Expected adverse event	N (%)
Burning sensation	1 (11.1%)
Rash	0 (0.0%)

reported (fatigue). In 10 d of follow-up, mild AEs were reported by four patients; all but one patient were free of AEs starting at day 3 (Table 3). One instance of burning sensation was reported by patient 1 from days 2–5 (Table 4), and resolved without intervention by day 6.

Patient 1, receiving treatment to the right rib cage, reported several AEs (in addition to the expected AE of burning sensation) throughout the 10-d follow-up period. Along with other localized AEs of itching and pain that persisted throughout follow-up (Table 3), he reported diffuse symptoms throughout the follow-up period such as headache, leg numbness, lethargy and lower back pain. This patient had known diffuse bony metastases compressing the spinal cord and various comorbidities; it is therefore unlikely that these AEs were related to the study procedure.

Efficacy

During the 10-d follow-up period, eight patients experienced a partial response to treatment and one patient experienced a complete response (Table 5); best responses had varying durability. Only one patient (patient 8) reported pain progression from day 1 to day 3 of follow-up,

but eventually experienced partial response by day 6, indicating pain flare. In this patient's medical chart after the procedure, the patient had subjectively reported "significant pain relief" at the site by 1 mo post-procedure.

Although pain scores generally decreased over the 10 d after treatment, there was some variation in this trend; as discussed, patient 8 experienced pain flare, and patient 9 experienced a more variable pain trend. Although these two patients experienced some flare-up of pain at first, all patients except one experienced a decrease in pain by day 10 of follow-up (Fig. 1).

Five patients used opioid medications at baseline and throughout the 10-d follow-up period; three used a lower dose by day 10 (Fig. 1). The OMED of patient 7 increased slightly from 20 mg/d at baseline to 30 mg/d at day 10, coupled by a reduction in pain score from 9 to 6. Patient 4, with a large increase in the OMED, had diffuse bone metastases and other comorbid conditions and was admitted for reasons unrelated to the study during the 10-d follow-up period; these factors likely explained his substantial increase in OMED at day 3. In his medical chart 20 d post-procedure, the patient reported a pain score of 0 (compared with 9 at baseline), indicating a complete response to treatment.

The average pain score across all patients was 6.9 at baseline, and dropped to 3.2 at day 10 of follow-up; the average OMED also dropped over time, from 1343 to 345 mg/d (Fig. 2).

QOL

Across 15 questions in the C15-PAL questionnaire, the average score for 12 questions decreased from baseline to day 10 of follow-up (Q1–Q8 and Q11–Q14), indicating an overall increase in QOL (Fig. 3). For Q9 (nausea), the average score remained constant. For Q10 (constipation), the average score increased from 1.3 to 1.7. Although on 12 of the other questions scores decreased, for Q15 (overall QOL), the average score increased from 3.8 to 4.6.

Table 5. Overall pain response

Patient ID	Day 1	Day 2	Day 3	Day 4	Day 5	Day 6	Day 7	Day 8	Day 9	Day 10	Best response
1	PR	PR	PR	PR	PR	IR	PR	PR	IR	IR	PR
2*	PR	PR	PR	PR	PR	PR	PR	PR	PR	PR	PR
3	IR	PR	PR	PR	PR	PR	PR	PR	PR	PR	PR
4*	PR	PR	IR	IR	IR	IR	IR	IR	IR	IR	PR
5	PR	PR	PR	PR	PR	PR	PR	PR	PR	PR	PR
6	IR	PR	PR	PR	PR	CR	CR	CR	CR	CR	CR
7	IR	IR	PR	PR	PR	PR	IR	IR	IR	IR	PR
8	Prog [†]	Prog	Prog	IR	IR	PR	IR	IR	PR	PR	PR
9	PR	IR	PR	IR	PR	IR	IR	PR	PR	PR	PR

PR = partial response; IR = indeterminate response; CR = complete response; Prog = progression

* Group 2 patients.

† Progression in patient 8 indicates pain flare.

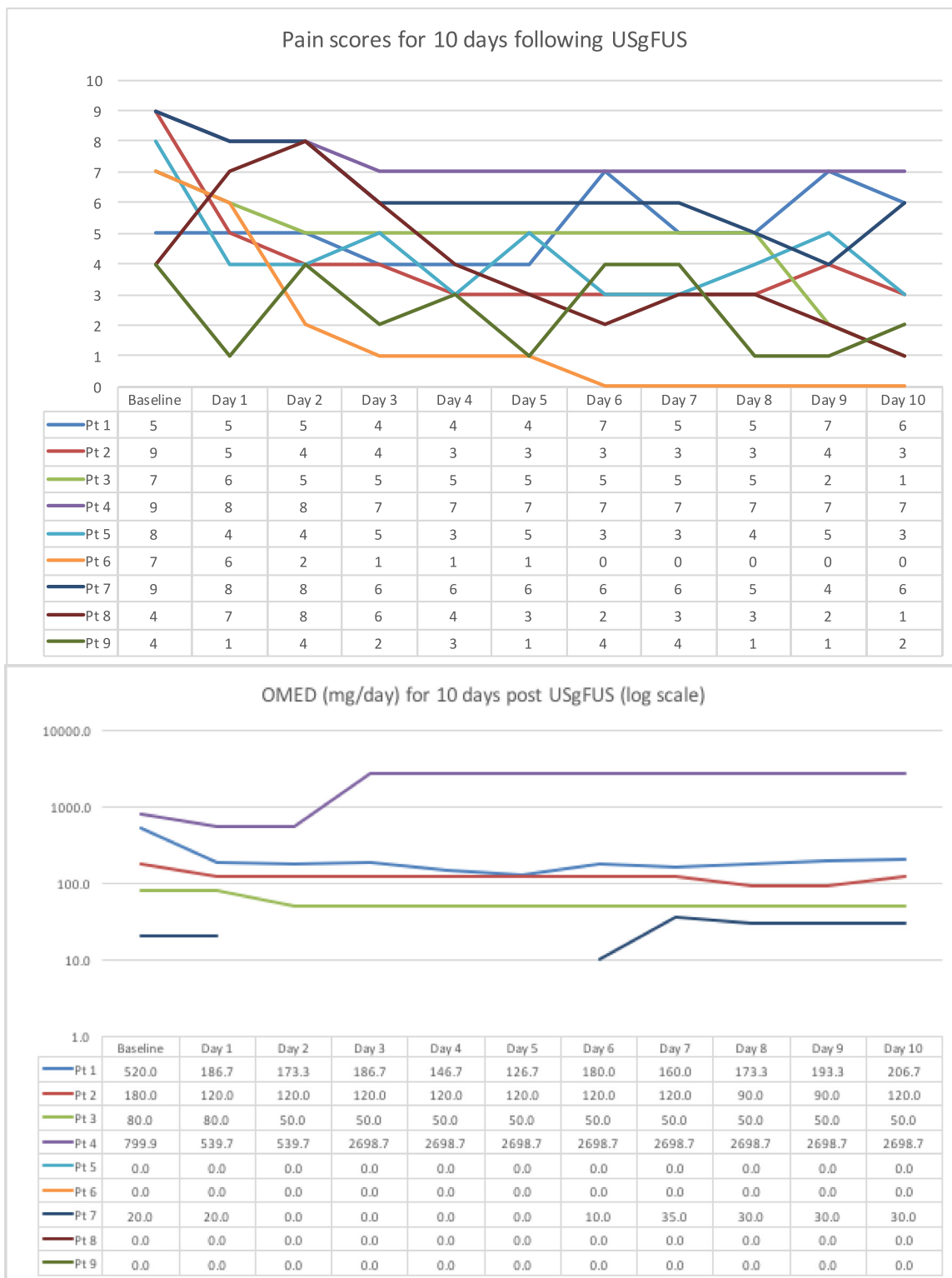


Fig. 1. Pain scores and daily OMED for the 10 d after USgFUS. OMED=oral morphine equivalent dose; USg-FUS = ultrasound-guided focused ultrasound.

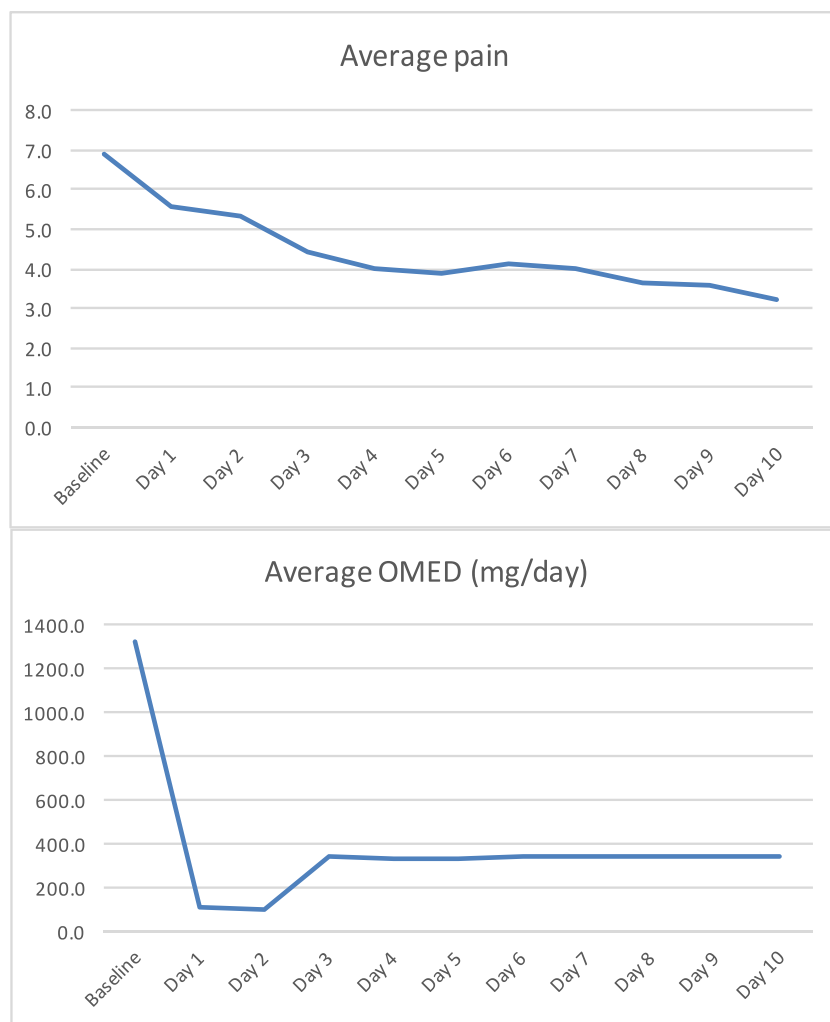


Fig. 2. Average pain and daily OMED over 10-d follow-up period. OMED = oral morphine equivalent dose.

Across 22 questions in the BM22 questionnaire, the average score for 21 questions decreased from baseline to day 10 of follow-up (Q1–Q4 and Q6–Q22), indicating an increase in QOL (Fig. 3). The average score for Q5 (pain felt in buttocks) increased from 1.3 to 1.6.

Durability of pain response and further treatment

On the basis of medical charts (average follow-up: 7 mo), six of nine patients had significant or total pain relief at the treated site indefinitely, with no indication of pain recurrence. Two patients (patients 1 and 2) reported a recurrence of pain 13 and 30 d post-procedure, respectively, and one patient (patient 7) reported worsening of pain 11 d post-procedure. These patients had three of the largest lesions, at 5.0×5.6 , 4.5×1.9 and 5.2×3.5 cm (Table 2).

Five patients elected to receive EBRT within 2 mo after USgFUS (group 1: four patients, group 2: one patient). All five patients had significant durable relief post-EBRT indefinitely, and did not require further

treatment according to their medical charts. The four patients who did not receive EBRT post-USgFUS also had significant durable pain relief, with no further treatment required.

On comparison of groups 1 (radiation naïve) and 2 (previously radiated), there did not appear to be a difference in the onset and durability of pain response.

DISCUSSION

In this pilot study, USgFUS for the palliation of bone metastases was found to be safe, tolerable and potentially beneficial in reducing pain and improving QOL.

Our study obtained outcomes in pain response and QOL comparable with those of previous studies evaluating MRgFUS for painful bone metastases. In a recent pilot study of MRgFUS (n = 10), Chan et al. (2017) found that overall pain scores decreased over the 30-d follow-up period; the procedure was reported to be safe and tolerable, with no treatment-related AEs. During the

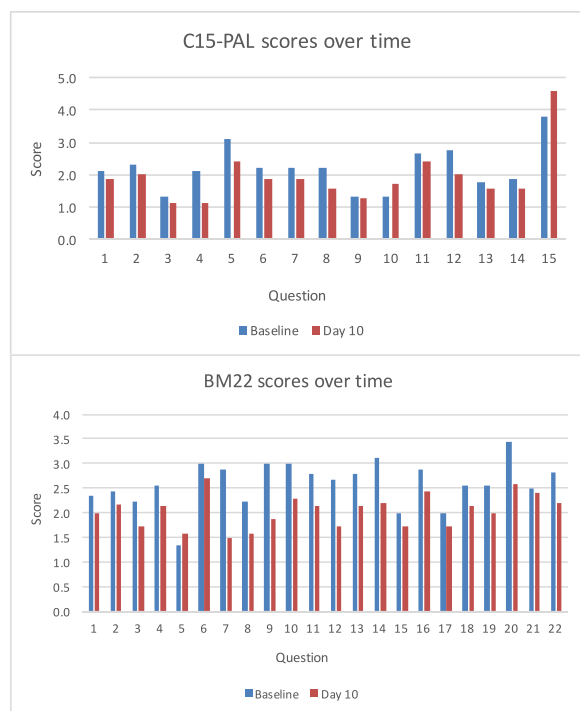


Fig. 3. EORTC C15-PAL and EORTC BM22 scores at baseline and day 10 follow-up. C15-PAL = European Organization for Research and Treatment of Cancer Quality of Life Questionnaire (EORTC QLQ) Core-15-Palliative; BM22 = EORTC QLQ Bone Metastases-22.

procedure, 8 of 10 patients pressed the stop button when the treatment became painful and needed to be adjusted. In 2014, Hurwitz *et al.* (2014) published a randomly allocated controlled trial comparing MRgFUS with placebo ($n=197$). Patients were consciously sedated or placed under general anesthetic. This study found significantly more responders in the MRgFUS arm than in the placebo arm and more improved pain relief and QOL. The majority of the 63 reported AEs were minor; however, there were several severe AEs including pathologic fractures, third-degree skin burns and neuropathy. Additionally, 5 patients in their study did not complete the procedure because of significant pain or procedure length.

Compared with these previous studies evaluating MRgFUS, our procedure using USgFUS was less painful, as no patients terminated the procedure because of pain. Additionally, our study did not produce any serious AEs. Furthermore, patients remained alert and awake throughout the treatment, receiving only light conscious IV sedation with small doses of IV versed and analgesics; this potentially indicates better tolerance of USgFUS. Periosteal infiltration with bupivacaine before treatment allowed us to minimize doses of IV sedation, and injection of fluid into the periosteum did not seem to affect the behavior of the ultrasound wave. One previous

study evaluated USgFUS in patients with malignant bone tumors, including 12 patients with bone metastases; although they found that USgFUS improved pain scores among all patients, their procedure utilized general anesthetic and they reported more AEs than the present study, with 48% of patients experiencing first-degree burns, 8.0% experiencing second-degree burns and 12.0% of patients lacking feeling in the affected limb.

The flexibility of the USgFUS articulated arm allowed our team to move the device to target the lesion and position patients comfortably, rather than moving the patient to the device. As such, general anesthesia was not required to immobilize patients. Receiving only conscious sedation also reduced the burden on patients, during both treatment and recovery. Ablations were performed quickly, with relatively little pain and short recovery and discharge times. Our procedure was also shorter, with an average of 32.4 min compared with 83 min in the Hurwitz *et al.* (2014) MRgFUS trial.

According to a meta-analysis, the overall responses to palliative EBRT for bone metastases range from 71%–73% (Bedard *et al.* 2014). Although all patients in our study experienced at least partial response at some point after the procedure, when evaluating long-term durability of pain response, six of nine patients (66.7%) had durable pain relief as determined through medical records. All five patients treated with EBRT after the USgFUS procedure had significant pain relief at the site with no pain flare in their subsequent clinical notes. This is promising, as it indicates potential utility in performing USgFUS concomitantly with palliative EBRT; using these therapies together may improve pain response compared with use of EBRT alone.

Although most patients in our study experienced pain relief within 1 d, one patient did experience pain flare. According to the medical chart after the procedure, the patient had reported total pain relief within 1 mo, which was still present nearly 10 mo after USgFUS without subsequent EBRT. Because of the pain response experienced after an initial flare-up, we determined this phenomenon to be pain flare, consistent with a previously established definition (Hird *et al.* 2009). In a previous study of 189 bone metastases in patients receiving palliative EBRT, the incidence of pain flare was 40% with a median duration of pain flare of 1.5 d (Hird *et al.* 2009); in the present study of USgFUS, only one patient (11.1%) experienced pain flare, which was resolved by day 6.

During this pilot study, our team was concerned with primarily safety and tolerability. Because of our conservative approach, we likely treated smaller targets more completely than larger targets. Accordingly, we potentially could have treated larger volumes but given that this was the first trial evaluating this device, we elected to be cautious. As the three patients who experienced pain recurrence or progression had the largest

lesions, there is likely a correlation between extent of treatment and efficacy.

This pilot study indicated promising results for pain response and QOL, as well as safety and tolerability. As there was virtually no difference between group 1 and group 2 patients, there is a potential for clinical utility in both patients who have prior EBRT and those who prefer to save their EBRT for a later date or forego it altogether. For six of our nine patients, only one treatment was needed to achieve durable pain response, which indicates applicability in patients who live far from hospital centers. Furthermore, for all five patients who received subsequent EBRT after the procedure (regardless if they had experienced pain relief after USgFUS), there was significant if not complete pain relief of the treated site; this finding potentially indicates the clinical utility of combining USgFUS with EBRT for superior pain control. However, future studies are required to determine the utility of this combined treatment as there are several patient factors that could have affected this finding in our study.

This study had several limitations. With a relatively short follow-up time of 10 d, information on durability of pain response came from medical records retrospectively. This study was also limited by its small sample size. Furthermore, we used considerable caution when treating patients to maximize safety and tolerability; potentially, the procedure could have produced more pronounced and longer-lasting benefits had we tried to maximize treatment. A phase II study is indicated to monitor the efficacy of USgFUS; having verified the safety and tolerability in this phase I pilot study, our team would aim to more aggressively and completely treat the entire lesion in patients who could tolerate a potentially longer treatment.

CONCLUSIONS

This pilot study provides evidence of the safety and tolerability of USgFUS in the palliation of painful bone metastases. On average, pain score and analgesic consumption decreased over the follow-up period, indicating pain relief; QOL also appeared to improve on average. Furthermore, USgFUS was found to be effective in producing durable pain response in a majority of patients, with or without concomitant EBRT. The results of this study are promising, and a phase II trial of the device is indicated in this patient population.

Acknowledgments—This work was supported by the Canadian Cancer Society (Grant 703887). Doctors Hynynen and David are senior investigators of this study, and Dr. David is the senior author of this article. We thank all the patients and research assistants in this project.

Conflict of interest disclosure—The authors declare no conflicts of interest.

SUPPLEMENTARY MATERIALS

Supplementary material associated with this article can be found in the online version at doi:10.1016/j.ultrasmedbio.2020.01.032.

REFERENCES

- Bedard G, Hoskin P, Chow E. Overall response rates to radiation therapy for patients with painful uncomplicated bone metastases undergoing initial treatment and retreatment. *Radiother Oncol* 2014;112:125–127.
- Catane R, Beck A, Inbar Y, Rabin T, Shabshin N, Hengst S, Pfeffer RM, Hanannel A, Dogadkin O, Liberman B, Kopelman D. MR-guided focused ultrasound surgery (MRgFUS) for the palliation of pain in patients with bone metastases—Preliminary clinical experience. *Ann Oncol* 2007;18:163–167.
- Chan M, Dennis K, Huang Y, Mougnot C, Chow E, DeAngelis C, Coccagna J, Sahgal A, Hynynen K, Czarnota G, Chu W. Magnetic resonance-guided high-intensity focused ultrasound for palliation of painful skeletal metastases: A pilot study. *Technol Cancer Res Treat* 2017;16:570–576.
- Chow E, Wu JS, Hoskin P, Coia LR, Bentzen SM, Blitzer PH. International consensus on palliative radiotherapy endpoints for future clinical trials in bone metastases. *Radiother Oncol* 2002;64:275–280.
- Chow E, Hoskin P, Mitera G, Zeng L, Lutz S, Roos D, Hahn C, van der Linden Y, Hartsell W, Kumar E. Update of the international consensus of palliative radiotherapy endpoints for future clinical trials in bone metastases. *Int J Radiat Oncol Biol Phys* 2012;82:1730–1737.
- Gianfelice D, Gupta C, Kucharczyk W, Bret P, Havill D, Clemons M. Palliative treatment of painful bone metastases with MR imaging-guided focused ultrasound. *Radiology* 2008;249:355–363.
- Harding D, Giles SL, Brown MRD, Ter Haar GR, van den Bosch M, Bartels LW, Kim YS, Deppe M, deSouza NM. Evaluation of quality of life outcomes following palliative treatment of bone metastases with magnetic resonance-guided high intensity focused ultrasound: An international multicentre study. *Clin Oncol (R Coll Radiol)* 2018;30:233–242.
- Hartsell WF, Scott CB, Bruner DW, Scarantino CW, Ivker RA, Roach M, III, Suh JH, Demas WF, Movsas B, Peterson IA, Konski AA, Cleeland CS, Janjan NA, DeSilvio M. Randomized trial of short-versus long-course radiotherapy for palliation of painful bone metastases. *J Natl Cancer Inst* 2005;97:798–804.
- Hird A, Chow E, Zhang L, Wong R, Wu J, Sinclair E, Danjoux C, Tsao M, Barnes E, Loblaw A. Determining the incidence of pain flare following palliative radiotherapy for symptomatic bone metastases: Results from three Canadian cancer centers. *Int J Radiat Oncol Biol Phys* 2009;75:193–197.
- Huisman M, ter Haar G, Napoli A, Hananel A, Ghanouni P, Lovey G, Nijenhuis RJ, van den Bosch MAAJ, Rieke V, Majumdar S, Marchetti L, Pfeffer RM, Huwitez MD. International consensus on use of focused ultrasound for painful bone metastases: Current status and future directions. *Int J Hyperthermia* 2015;31:251–259.
- Hurwitz MD, Ghanouni P, Kanaev SV, Iozeffi D, Gianfelice D, Fennessy FM, Kuten A, Meyer JE, LeBlang SD, Roberts A, Choi J, Larner JM, Napoli A, Turkevich VG, Inbar Y, Tempany CMC, Pfeffer RM. Magnetic resonance-guided focused ultrasound for patients with painful bone metastases: Phase III trial results. *J Natl Cancer Inst* 2014;106:1–9.
- Joo B, Park MS, Lee SH, Choi HJ, Lim ST, Rha SY, Rachmilevitch I, Lee YH, Suh JS. Pain palliation in patients with bone metastases using magnetic resonance-guided focused ultrasound with conformal bone system: A preliminary report. *Yonsei Med J* 2015;56:503–509.
- Liberman B, Gianfelice D, Inbar Y, Beck A, Rabin T, Shabshin N, Chander G, Hengst S, Pfeffer R, Chechick A, Hanannel A, Dogadkin O, Catane R. Pain palliation in patients with bone metastases using MR-guided focused ultrasound surgery: A multicenter study. *Ann Surg Oncol* 2009;16:140–146.
- Lutz S, Berk L, Chang E, Chow E, Hahn C, Howell D, Konski A, Kachnic L, Lo S, Sahgal A, Silverman L, von Gunten C, Mendel E, Vassil A, Watkins Bruner D, Hartsell W. Palliative radiotherapy

- for bone metastases: An ASTRO evidence-based guideline. *Int J Radiat Oncol Biol Phys* 2011;79:965–976.
- Marinova M, Rauch M, Mücke M, Rolke R, Gonzalez-Carmona MA, Henseler J, Cuhls H, Radbruch L, Strassburg CP, Zhang L, Schild HH, Strunk HM. High-intensity focused ultrasound (HIFU) for pancreatic carcinoma: Evaluation of feasibility, reduction of tumour volume and pain intensity. *Eur Radiol* 2016;26:4047–4056.
- McDonald R, Chow E, Rowbottom L, DeAngelis C, Soliman H. Incidence of pain flare in radiation treatment of bone metastases: A literature review. *J Bone Oncol* 2014;3:84–89.
- Namba H, Kawasaki M, Izumi M, Ushida T, Takemasa R, Ikeuchi M. Effects of MRgFUS treatment of musculoskeletal pain: Comparison between bone metastasis and chronic knee/lumbar osteoarthritis [Epub ahead of print.]. *Pain Res Manag* 2019. doi: 10.1155/2019/4867904. Accessed October 31, 2019.
- Napoli A, Anzidei M, Marincola BC, Brachetti G, Ciolina F, Cartocci G, Marsecano C, Zaccagna F, Marchetti L, Cortesi E, Catalano C. Primary pain palliation and local tumor control in bone metastases treated with magnetic resonance-guided focused ultrasound. *Invest Radiol* 2013;48:351–358.
- National Cancer Institute. Common Terminology Criteria of Adverse Events (CTCAE), Version 5.0. November 27, 2017. Available at: https://ctep.cancer.gov/protocolDevelopment/electronic_applications/docs/CTCAE_v5_Quick_Reference_8.5x11.pdf.
- Orgera G, Monfardini L, Della Vigna P, Zhang L, Bonomo G, Arnone P, Padrenostro M, Orsi F. High-intensity focused ultrasound (HIFU) in patients with solid malignancies: Evaluation of feasibility, local tumour response and clinical results. *Radiol Med* 2011;116:734–748.
- Poulsen H, Nielsen O, Klee M, Rorth M. Palliative irradiation of bone metastases. *Cancer Treat Rev* 1989;16:41–48.
- Valero P, Gomez-Gonzalez E, Sabino A, Valero M, Suarez-Ramos J. Magnetic-resonance-guided focused ultrasound surgery in the treatment of oncology patients—Fundamentals and review of early clinical applications. *Eur Oncol* 2010;6:76–79.
- von Moos R, Body JJ, Egerdie B, Stopeck A, Brown J, Fallowfield L, Patrick DL, Cleeland C, Damyantov D, Palazzo FS, Marx G, Zhou Y, Braun A, Balakumaran A, Qian Y. Pain and analgesic use associated with skeletal-related events in patients with advanced cancer and bone metastases. *Support Care Cancer* 2016;24:1327–1337.