34th Annual International Conference of the IEEE EMBS
San Diego, California USA, 28 August - 1 September, 2012

Quantitative Ultrasound Spectral Parametric Maps: Early Surrogates of Cancer Treatment Response*

Ali Sadeghi-Naini, *Member, IEEE*, Omar Falou, *Member, IEEE*, and Gregory J. Czarnota

***Abstract*— Textural characteristics of quantitative ultrasound spectral parametric maps have been proposed for the first time to predict cancer therapy response, early following treatment initiation. Such an early prediction can facilitate personalized medicine in cancer treatment procedures. Patients (*n=10*) with locally advanced breast cancer received neo-adjuvant chemotherapy, as "up-front" treatment, followed by mastectomy with axillary nodal clearance. Data collection consisted of acquiring tumor ultrasound radio-frequency data prior to neo-adjuvant treatment onset and at 4 times during treatment, in addition to pathological examinations of resected specimens after mastectomy. Several textural features were extracted from parametric maps of mid-band fit and 0-MHz intercept. The relative changes of these features were calculated one week after the treatment commenced, compared to the pre-treatment scan. Statistical analysis performed suggested that five of the applied textural features exhibit statistically significant differences between clinically/pathologically responding and non-responding patients. The promising results obtained represent a substantial step forward towards customizing cancer therapies by using this quantitative imaging modality. This can facilitate the switch of an ineffective treatment for a specific patient to a salvage therapy within weeks, instead of having patient endures months of the ineffective treatment.**

I. Introduction

Personalized medicine is defined in part as altering an ineffective therapy for a specific patient to the one which is more efficacious for him/her. Monitoring specific response of a patient to the therapy regime using imaging methods is an important component of personalized medicine. In cancer treatment, standard anatomical based imaging can detect macroscopic changes in tumor size, but these often take many weeks to months to develop. Functional imaging methods including magnetic resonance imaging (MRI), and positron emission tomography (PET), have been demonstrated capable of detecting tumor responses early after starting therapy [1]. Such methods which frequently probe tumor physiology could be used to navigate changes in treatment non-invasively, in order to optimize the final prognosis. In this context, quantitative ultrasound (QUS) techniques have recently exhibited high capabilities for early probing changes in tissue microstructure associated with cancer therapies, *e.g.* apoptosis [2–6]. Ultrasound (US) imaging has the advantage of low cost, rapid imaging speed, portability and high resolution. Moreover, unlike the other modalities being investigated for treatment monitoring, no injections of contrast agents are needed since the image contrast and changes in spectral power are caused by changes in the physical properties of dying cells [2].

Patients with locally advanced breast cancer (LABC) represent a typical patient population which benefit from changing ineffective therapies to more efficacious treatments. Breast cancer is the most common malignancy for females in North America. Approximately 5-15% of the estimated 200,000 new cases diagnosed each year will present with LABC [7]. LABC has variable definitions, including Stage III or inoperable disease. The current treatment of LABC includes aggressive neo-adjuvant chemotherapy followed by surgery that is generally a mastectomy with axillary nodal clearance, followed by radiation and possibly Herceptin and or hormonal manipulation, if indicated [8], [9]. However, despite aggressive therapeutic combinations, the loco-regional recurrence rate for LABC patients remains high at 10-20% [10]. The search for the optimal LABC treatment remains controversial because determining the optimal treatment paradigm is fraught with uncertainties, both in terms of treatment regimen and duration of treatment [8]. While complete pathological response to neo-adjuvant chemotherapy has been shown to strongly correlate with patient survival [11] this prognostic factor is assessed at the time of surgery, as after which point the window for a neo-adjuvant treatment is closed. Conventional clinical surrogates based on anatomical information such as on-going physical assessment, and standard clinical imaging such as mammography, as well as B-mode US suffer from an inability to objectively assess treatment response early during the course of treatment [12]. This is while the early detection of patients' refractory to chemotherapy is critical. According to Huang *et al.*, salvage treatment for chemotherapy resistant (non-responsive) tumors with locally advanced breast cancer can result in a survival rate of 46% at 5 years [13].

In this study, textural properties of conventional-frequency QUS spectral parametric maps have been proposed for the first time to predict cancer therapy response,

*This research has been supported by the Terry Fox Foundation, Canadian Institutes of Health Research (CIHR), and Canadian Breast Cancer Foundation (CBCF).

A. Sadeghi-Naini is with the Departments of Medical Biophysics and Radiation Oncology, University of Toronto, Toronto, ON, Canada; also with Departments of Imaging Research and Radiation Oncology, Sunnybrook Health Sciences Centre, Toronto, ON, Canada (phone: 416-480-6100 x83719; fax: 416-480-6002; e-mail: Ali.Sadeghi-Naini@sunnybrook.ca).

O. Falou is with the Departments of Medical Biophysics and Radiation Oncology, University of Toronto, Toronto, ON, Canada; also with Departments of Imaging Research and Radiation Oncology, Sunnybrook Health Sciences Centre, Toronto, ON, Canada (e-mail: Omar.Falou@sunnybrook.ca).

G. J. Czarnota is with the Departments of Medical Biophysics and Radiation Oncology, University of Toronto, Toronto, ON, Canada; also with Departments of Imaging Research and Radiation Oncology, Sunnybrook Health Sciences Centre, Toronto, ON, Canada (e-mail: Gregory.Czarnota@sunnybrook.ca).

TABLE I. PARTICIPATING PATIENTS' CHARACTERISTICS

Characteristic	Value
Mean Age	45 years (range: 36-57)
Menstrual Status Prior to Treatment	
Pre-menopausal	9 patients
Post-menopausal	1 patient
Mean Maximum Tumor Size	7.9 ± 2.7 cm (rang: 4-13 cm)
Tumor Histology	
Ductal Carcinoma	10 patients
Hormone receptor (estrogen or progesterone receptor)	
Positive	6 patients
Negative	4 patients
Triple Negative (estrogen, progesterone, Her-2-neu)	2 patients
Mean Body Mass Index	27.4 ± 13 (range: 57.8-18.2)

early following treatment initiated. Such prediction can offer a better prognosis for patients since treatment alterations can be made or salvage regimens instituted, *i.e.* it can facilitate personalized medicine in cancer treatment procedures. A clinical study was performed to investigate the efficacy of textural characteristics of QUS images to distinguish between clinically/pathologically responding and non-responding patients, as early as one week after treatment commenced. Patients (*n=10*) with locally advanced breast cancer received neo-adjuvant chemotherapy, as "up-front" treatment, followed by a mastectomy with axillary nodal clearance. Data collection consisted of acquiring tumor US images and radio-frequency data prior to neo-adjuvant treatment onset and at 4 times during treatment (weeks 1, 4, and 8, and pre-operatively). In addition, pathology examinations were performed on the resected specimens after mastectomy through three-dimensional whole mount histopathology where data on size, grade, histologic subtype, and tumor response were recorded. Three texture features, namely contrast, correlation, and homogeneity, were extracted from parametric maps of mid-band fit and 0-MHz intercept. The relative changes of these six texture features were calculated one week after the treatment initiated, compared to the pre-treatment scan. Statistical analysis performed on the determined textural features suggested that five of the applied parameters exhibit statistically significant differences between clinically/pathologically responding and non-responding patients. The promising results obtained implied a very good potential for texture features of QUS spectral parametric maps, acquired only one week after the chemotherapy initiation, for detecting clinical/pathological response in the tumor, which may be completed many months later.

II. Material and Methods

A. Study Protocol and Data Collection

This study was conducted with research ethics approval. After informed consent was obtained for participation, US data was acquired at 5 times during each patient's course of treatment. The first scan was acquired prior to the start of chemotherapy which was used as a baseline of comparison for subsequent scans. The following three scans were acquired during the first, fourth and eighth week of treatment, with a fifth scan acquired within one week prior to the modified radical mastectomy surgery, typically occurring four to six weeks after the course of treatment was complete.

US data was acquired with patients lying supine with their arms above their heads. Conventional B-mode and radio-frequency US data were acquired using a Sonix RP system, (Ultrasonix, Vancouver, Canada) utilizing a 6 cm L14-5 transducer pulsed at 10 MHz resulting in a central frequency of approximately 7 MHz. In the majority, focal depths remained consistent for individual patients throughout the study. Breast regions selected for US scanning were directed by an oncologist who determined acquisition scan planes via physical examination of the patient following a review of the patients' charts.

Prior to joining the study, all patients underwent a core needle biopsy to confirm a cancer diagnosis. Pre-treatment imaging of patients included an MRI of the breast and a metastatic workup as necessary as part of the institutional standard of care for such patients. Patients were followed clinically by various oncologists who remained blinded to the study results. Examination by clinicians was conducted at each follow-up time and assessment of tumor size recorded. Following surgery, patient mastectomy specimens were mounted on full-mount pathology slides and examined by a pathologist who also remained blinded to study results. All cases were examined by the same pathologist, who provided information regarding tumor size, grade, extent of cellularity, histological subtype and tumor response. For the purposes of this study, patients were categorized into two groups, those exhibiting a good response to treatment (responder) and those which exhibited a poor response (non-responder). This assessment was based upon changes in overall tumor volume during the course of treatment. Patients were considered good responders if there was a decrease in tumor volume of 50% or more, and included patients which were deemed to have a complete pathological response to treatment, thus having no residual malignancy. Conversely, patients were deemed to be poor responders if there was less than a 50% decrease in tumor volume and included patients with progressive disease in which the tumor volume increased despite treatment administration. In cases where tumor volume decrease was insufficient in categorizing a patient's response, additional information was garnered through changes in tumor cellularity ascertained via pathological examination. The participating patients' characteristics are summarized in TABLE I. Among the participating patients, seven patients had a good clinical/pathological response and classified as responders, while three patients had poor clinical/pathological responses, and hence were considered as non-responders.

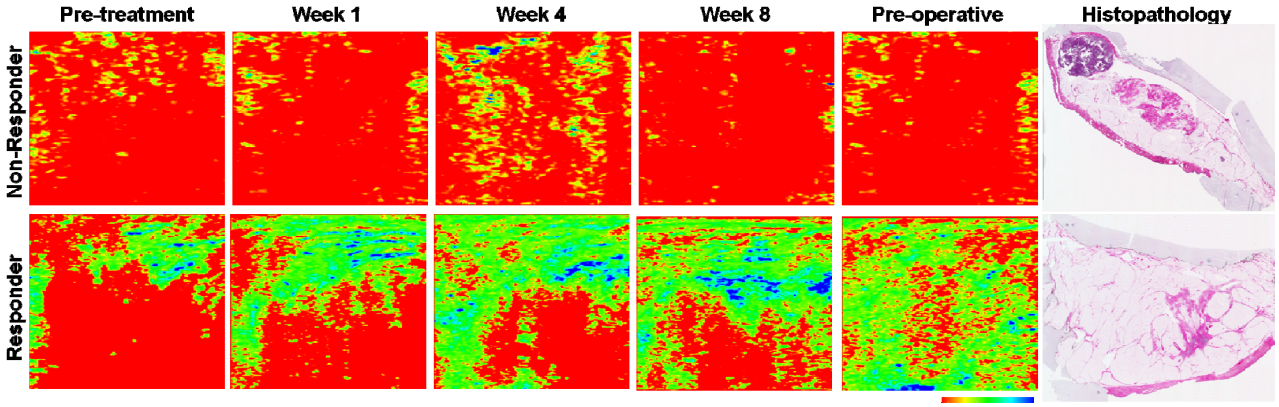

Figure 1: Representative data obtained from clinically/pathologically responder and non-responder patients: Parametric maps of quantitative ultrasound spectral 0-MHz intercept, as well as light microscopy images of whole mount histopathology obtained following modified radical mastectomy surgery, for non-responder (top) and responder (bottom) patients. Ultrasound data were acquired prior to treatment, at weeks 1, 4, and 8 during treatment and prior to surgery, respectively. The color bar represents a scale encompassing ~70 dBr. The non-responder patient (left) has a residual metastasis of approximately 3 cm, while pathological analysis of the responder patient found no detectable residual disease.

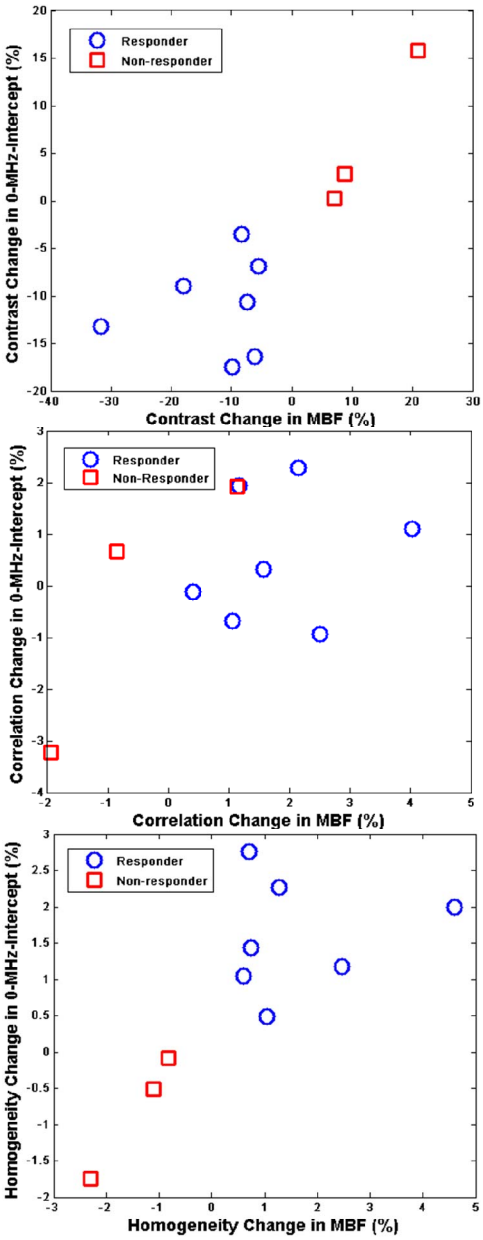

Figure 2. Scatter data plots for the relative changes in textural characteristics of the mid-band fit and 0-MHz intercept

TABLE II. *P*-VALUES OBTAINED FROM STATISTICAL TESTS OF SIGNIFICANCE (RESPONDERS VS. NON-RESPONDERS)

Textural Feature	Mid-Band Fit	0-MHz Intercept
Contrast	*0.0042***	*0.0033***
Correlation	*0.0282**	*0.5355*
Homogeneity	*0.0101**	*0.0028***

*, and ** denote *'statistically significant'*, and *'statistically highly significant'*, respectively.

B. US Data Analysis

US radiofrequency data analysis was performed using linear regression analysis of the normalized power spectrum [2–6]. US data was analyzed across all acquired planes through the scan volume which included identifiable tumor regions. Analysis was performed upon a region of interest (ROI) located at the tumour centre. Selection of the tumor regions was conducted with the help of an oncologist accustomed to working with US images of breast tumors.

The power spectrum was calculated using a Fourier transform of the raw radiofrequency data for each scan line through the ROI and subsequently averaged. In order to remove the effects of system transfer functions, transducer beam-forming and diffraction artefacts in addition to acting as a mechanism of depth related attenuation correction data were normalized with the averaged power spectrum obtained from an agar embedded glass bead phantom model with properties similar to those of breast tissue (modified from [14]). Phantom data was acquired for each setting used during patient data acquisition including variations in gain, image and focal depths and normalization curves obtained from regions equivalent in size and location to those of regions of interest selected for analysis.

Linear regression analysis was performed within a -6 dB window from the transducer central frequency determined from a calibration pulse in order to generate a best fit line. Parameters subsequently determined include the mid-band fit (MBF), and the corresponding 0-MHz intercept [15], [16]. Parametric maps of determined spectral parameters were generated by displaying the results of a sliding window analysis on a pixel by pixel basis for a visual indication of the RF data analysis, as well as for texture analysis procedure. Parametric parameters were obtained from a sliding

Hamming window of approximately 9-11 wavelengths in the axial direction and 15 scans lines laterally.

Texture analysis on the generated spectral parametric maps was performed based on a gray-level co-occurrence matrix (GLCM), which represents the angular relationship between neighboring pixels as well as the distance between them [17], [18]. GLCM textural parameters may be considered, in this context, as second order statistics of the values over the parametric map. Three textural parameters of contrast, correlation, and homogeneity, were extracted from the corresponding GLCM of each spectral parametric map. Parameters were determined for each of the scan planes collected per patient visit and subsequently averaged across the tumor volume. The relative changes of the six textural features were calculated one week after the treatment started, compared to the pre-treatment scan.

III. Results

Figure 1 shows representative QUS data obtained from a clinically/pathologically responder and non-responder patients. As it can be seen changes in textural properties of the 0-MHz intercept parametric maps are clearly detectable for the clinically responding patient, whereas they remain negligible in the case of clinically non-responding patient, during the course of neo-adjuvant chemotherapy. This figure also presents the corresponding histological samples obtained following modified radical mastectomy surgery. These samples show that the non-responder patient has a residual metastasis of approximately 3 cm, while pathological analysis of the responder patient found no detectable residual disease. Figure 2 demonstrates the scatter data plot for the relative changes in contrast, correlation, and homogeneity of the mid-band fit and 0-MHz intercept one week after treatment initiation, respectively. In order to evaluate the extracted textural parameters as early indications of treatment response, tests of significance (responders vs. non-responders) based on changes in the determined parameters were carried out using *t*-test (unpaired, two-sided, $\alpha=0.05$). The *p*-values obtained from tests are outlined in TABLE II.

IV. Discussion and Conclusion

A technique was proposed in this paper for early prediction of cancer therapy response using textural characteristics of spectral parametric maps of QUS. Obtained results reported promising properties for such parameters as early surrogates of cancer treatment response. A favorable agreement was found between early changes in the determined parameters and ultimate clinical/pathological response, which may be completed many months later (Figure 1). Plots of the scatter data (Figure 2) suggest that while distributions of responders and non-responders patients are quite separable in the contrast and homogeneity spaces, these distributions approached together in the correlation space where the samples are not linearly separable. Conducted tests of significance (TABLE II) demonstrated that relative changes in correlation and homogeneity of the mid-band fit is statistically different, while relative changes in contrast of mid-band fit and 0-MHz intercept as well as in homogeneity of the 0-MHz intercept is statistically highly significant between clinically/pathologically responder and non-responder patients, one week after the start of therapy. The encouraging results obtained will pave the way for personalizing cancer therapies by using this quantitative imaging modality.

Acknowledgment

The Authors thank Naum Papanicolau, Sara Iradji, and Ervis Sofroni for their help towards conducting this research.

References

[1] K. Brindle, "New approaches for imaging tumour responses to treatment.," *Nature reviews. Cancer*, vol. 8, no. 2, pp. 94-107, Feb. 2008.

[2] G. J. Czarnota et al., "Ultrasonic biomicroscopy of viable, dead and apoptotic cells," *Ultrasound in medicine & biology*, vol. 23, no. 6, pp. 961-5, Jan. 1997.

[3] G. J. Czarnota et al., "Ultrasound imaging of apoptosis: high-resolution non-invasive monitoring of programmed cell death in vitro, in situ and in vivo," *British journal of cancer*, vol. 81, no. 3, pp. 520-7, Oct. 1999.

[4] A. S. Tunis, G. J. Czarnota, A. Giles, M. D. Sherar, J. W. Hunt, and M. C. Kolios, "Monitoring structural changes in cells with high-frequency ultrasound signal statistics," *Ultrasound in medicine & biology*, vol. 31, no. 8, pp. 1041-9, Aug. 2005.

[5] B. Banihashemi, R. Vlad, B. Debeljevic, A. Giles, M. C. Kolios, and G. J. Czarnota, "Ultrasound imaging of apoptosis in tumor response: novel preclinical monitoring of photodynamic therapy effects," *Cancer research*, vol. 68, no. 20, pp. 8590-6, Oct. 2008.

[6] R. M. Vlad, S. Brand, A. Giles, M. C. Kolios, and G. J. Czarnota, "Quantitative ultrasound characterization of responses to radiotherapy in cancer mouse models," *Clinical cancer research*, vol. 15, no. 6, pp. 2067-75, Mar. 2009.

[7] D. A. Mankoff, L. K. Dunnwald, J. R. Gralow, G. K. Ellis, M. J. Drucker, and R. B. Livingston, "Monitoring the response of patients with locally advanced breast carcinoma to neoadjuvant chemotherapy using [technetium 99m]-sestamibi scintimammography," *Cancer*, vol. 85, no. 11, pp. 2410-23, Jun. 1999.

[8] G. N. Hortobagyi, "Comprehensive management of locally advanced breast cancer," *Cancer*, vol. 66, no. 6, pp. 1387-91, Sep. 1990.

[9] F. J. Esteva and G. N. Hortobagyi, "Locally advanced breast cancer," *Hematology/oncology clinics of North America*, vol. 13, no. 2, pp. 457-72, vii, Apr. 1999.

[10] S. H. Giordano, "Update on locally advanced breast cancer," *The oncologist*, vol. 8, no. 6, pp. 521-30, Jan. 2003.

[11] B. Fisher et al., "Effect of preoperative chemotherapy on the outcome of women with operable breast cancer," *Journal of clinical oncology*, vol. 16, no. 8, pp. 2672-85, Aug. 1998.

[12] E. Yeh et al., "Prospective comparison of mammography, sonography, and MRI in patients undergoing neoadjuvant chemotherapy for palpable breast cancer," *AJR. American journal of roentgenology*, vol. 184, no. 3, pp. 868-77, Mar. 2005.

[13] E. Huang et al., "Locoregional treatment outcomes for inoperable anthracycline-resistant breast cancer," *International journal of radiation oncology, biology, physics*, vol. 53, no. 5, pp. 1225-33, Aug. 2002.

[14] F. Dong, E. L. Madsen, M. C. MacDonald, and J. A. Zagzebski, "Nonlinearity parameter for tissue-mimicking materials," *Ultrasound in medicine & biology*, vol. 25, no. 5, pp. 831-8, Jun. 1999.

[15] F. L. Lizzi, M. Astor, T. Liu, C. Deng, D. J. Coleman, and R. H. Silverman, "Ultrasonic spectrum analysis for tissue assays and therapy evaluation," *International Journal of Imaging Systems and Technology*, vol. 8, no. 1, pp. 3-10, 1997.

[16] M. L. Oelze and W. D. O'Brien, "Method of improved scatterer size estimation and application to parametric imaging using ultrasound," *The Journal of the Acoustical Society of America*, vol. 112, no. 6, pp. 3053-63, Dec. 2002.

[17] R. M. Haralick, K. Shanmugam, and I. Dinstein, "Textural Features for Image Classification," *IEEE Transactions on Systems, Man, and Cybernetics*, vol. 3, no. 6, pp. 610-621, Nov. 1973.

[18] Y.-Y. Liao et al., "Classification of scattering media within benign and malignant breast tumors based on ultrasound texture-feature-based and Nakagami-parameter images," *Medical Physics*, vol. 38, no. 4, p. 2198, Apr. 2011.